

## Anterior Abdominal Muscle Exercises A Useful Pre-Operative Aid to Abdominoplasty

FAYEZ EL-DEEB, M.D., F.R.C.S.

Ahmad Maher Teaching Hospital, Cairo.

### ABSTRACT

Abdominoplasty is one of the common procedures in plastic surgical practice. This procedure addresses the redundancy in the anterior abdominal cutaneous panniculus and the anterior abdominal wall muscles. Plication of the weak anterior abdominal muscles causes significant post-operative discomfort during activities. The weak muscles reduce the quality of the post-operative result. Twenty-five patients, with age ranging from 24 years to 62 years, seeking abdominoplasty and with variable degrees of weak anterior abdominal muscles were encouraged into exercises for the anterior abdominal muscles for a period of 6 weeks - 6 months before the operation. Good tone of the anterior abdominal wall muscles was achieved in 23 patients. Two patients had weak anterior abdominal muscles and needed some plication. One patient had epigastric herniae that were repaired. A localized drain wound infection occurred in one patient. A seroma occurred in one patient. One patient continued to have some redundancy in the epigastric and hypochondrial regions which was corrected by a second later procedure of bilateral breast reduction. Post-operative contouring result was found better in the patients who achieved good tone of the muscles.

### INTRODUCTION

The first dermolipectomies of the abdominal wall were performed by surgeons who were repairing massive umbilical hernias [1]. Demars and Marx presented a case report of an abdominal wall lipectomy in France [2]. Desjardin resected a composite of skin and fat weighing 22.4 kg through a vertical elliptical abdominal incision [1].

In 1911, Amedée Morestin published 5 cases of dermolipectomy performed through transverse elliptical incisions [1]. Weinhold recommended a midline type of excision [1]. Jolly favoured a low transverse elliptical excision [1]. Regnault reported a lower transverse incision in the shape of a "W" [3]. Suction-assisted lipectomy was introduced in 1980's by Illouz [4] and Kesselring [5].

Plication of the rectus sheath corrects the diastasis recti. When this is not enough to correct the contour deformities of the anterior abdominal wall,

the waistline suture of Jackson can be done across the middle or the lower portion of the abdomen [1]. Another possible technique is the transposition of the external oblique fascia as described by Psillakis [6].

Nowadays, abdominoplasty is a common procedure in the general plastic practice, worldwide. The procedure deals with the problems of redundancies in the anterior abdominal skin and subcutaneous fat and the anterior abdominal muscles. Redundancy of the anterior abdominal skin and muscles presents in variable degrees.

The procedure of abdominoplasty includes dermolipectomy of the excess cutaneous panniculus  $\pm$  translocation of the umbilicus  $\pm$  plication of the anterior abdominal muscles  $\pm$  liposuction of localized adiposities. Weakness and redundancy of the anterior abdominal muscles reduce the quality of the post-operative result. Besides, plication of the anterior abdominal muscles was found to cause significant post-operative discomfort during activities.

The aim of this work is to document the useful effect of the abdominal muscle exercises on the abdominoplasty operation and the post-operative result.

### PATIENTS AND METHODS

Twenty-five patients seeking abdominoplasty, with variable degrees of weakness of the anterior abdominal muscles were studied. Patients' age ranged from 24 to 62 years, with a mean age of 38 years. Twenty-two patients were females and three patients were males. One patient had 2 associated epigastric herniae which were repaired during the abdominoplasty. One patient was diabetic with controlled diabetes type II. Two female patients

and one male patient had the pendulous abdomen after the treatment of their morbid obesity; where they lost significant amounts of weight.

All patients, except the patient with the epigastric herniae, had pre-operative regular exercises for the anterior abdominal muscles for 6 weeks - 6 months, in a fitness centre and at home. Patients were encouraged to loose weight as appropriate.

Infiltration with Bupivacaine and adrenaline in Hartman's solution was done at the incision site and resection area. The operation was done through a skin-line, a modified W, or inverted T with a short vertical stem incision in the lower abdomen. Dissection was done in the lower abdomen to allow resection and translocation of the umbilicus. In two patients, the dissection was done up to the costal margin and xiphisternum to allow plication of the rectus sheath  $\pm$  repair of herniae.

Eighteen patients had translocation of the umbilicus during the operation. Four patients had liposuction for localized adiposities in the lower

abdomen after the excision of excess abdominal apron.

## RESULTS

Good tone in the anterior abdominal muscles was achieved in 23 patients (92%). Two patients had weak anterior abdominal muscles and needed some plication. Post-operative abdominal contour was of better quality in the patients who achieved good tone in the abdominal muscles.

A localized left drain wound infection occurred in one patient and was treated with dressings and antibiotics. A seroma collected in one patient and was drained by needle aspiration. One post-gastroplasty patient continued to have some redundancy in the epigastric and hypochondrial regions which was corrected during a second later procedure of bilateral breast reduction.

Follow-up for 6-12 months after the operation showed no abnormal finding and patients were satisfied.

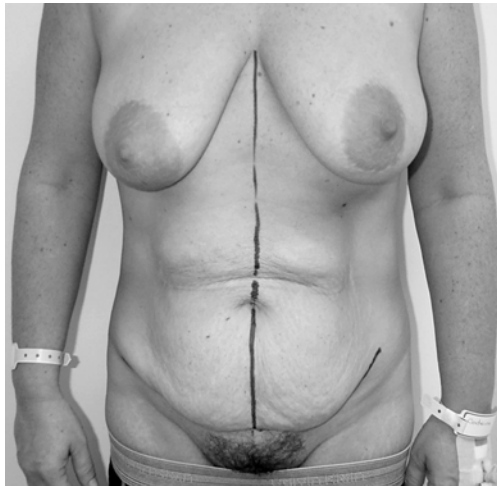

Fig. (1-A): Pre-operative, front-view.

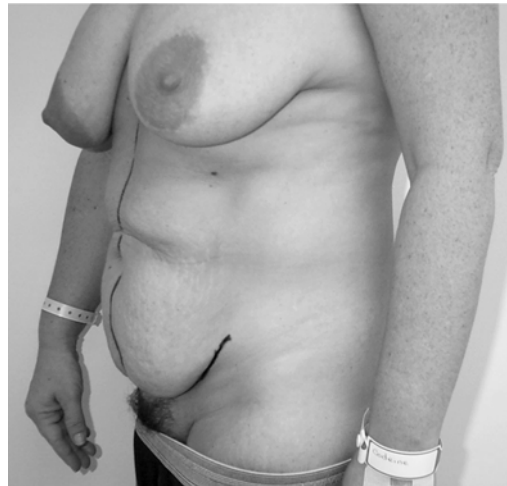

Fig. (1-B): Pre-operative, side-view.

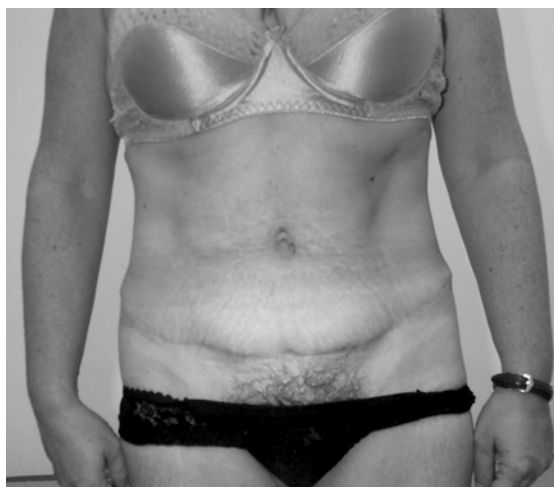


Fig. (1-C): Post-operative, front-view.

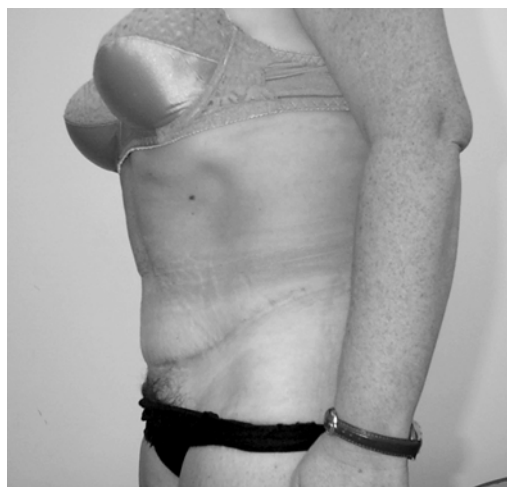


Fig. (1-D): Post-operative, side-view.

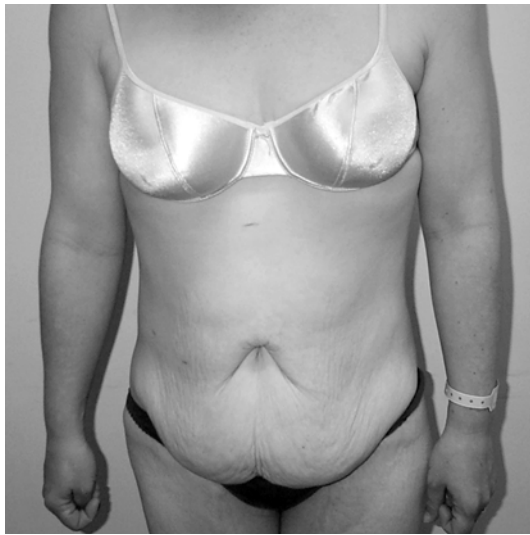

Fig. (2-A): Pre-operative, front-view.

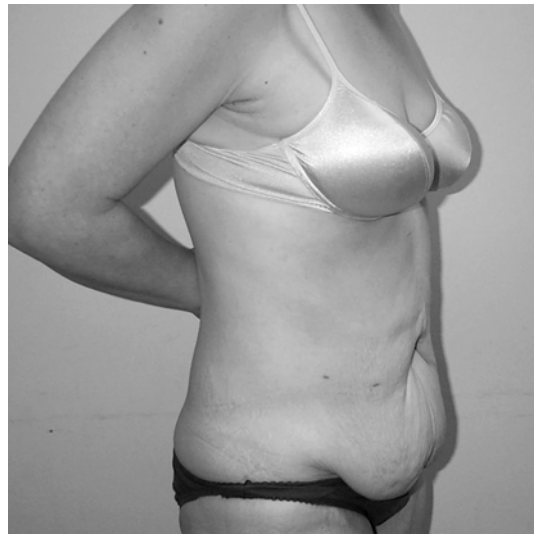

Fig. (2-B): Pre-operative, side-view.

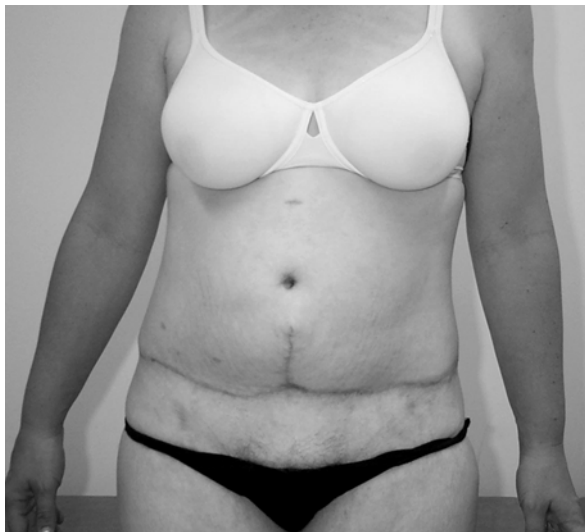

Fig. (2-C): Post-operative, front-view.

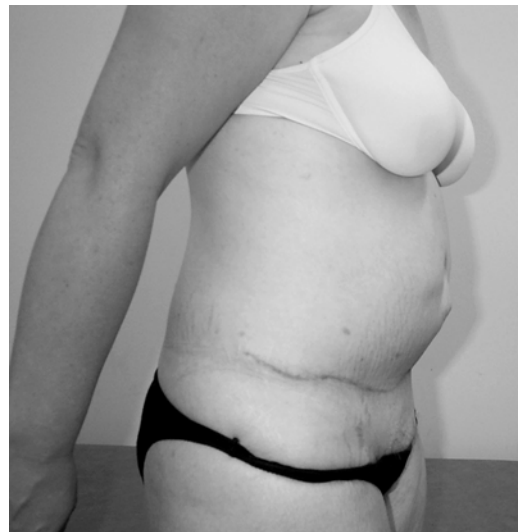

Fig. (2-D): Post-operative, side-view.

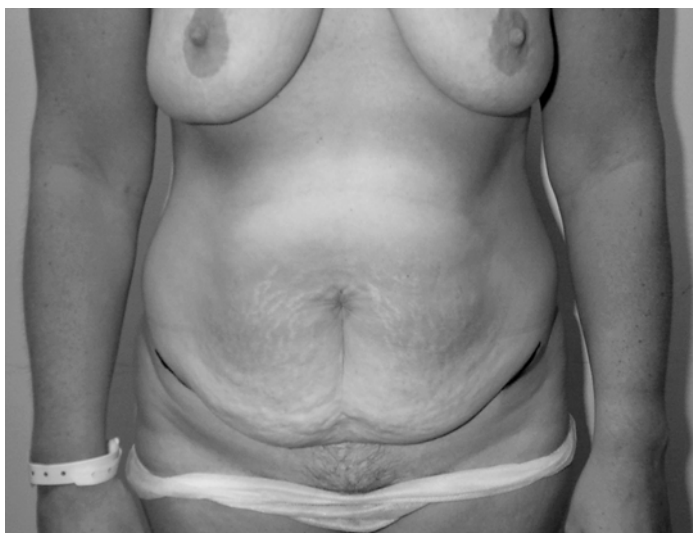

Fig. (3-A): Pre-operative, front-view.

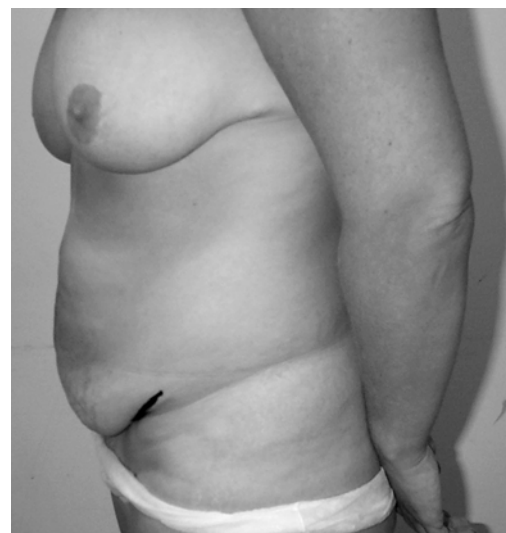

Fig. (3-B): Pre-operative, side-view.



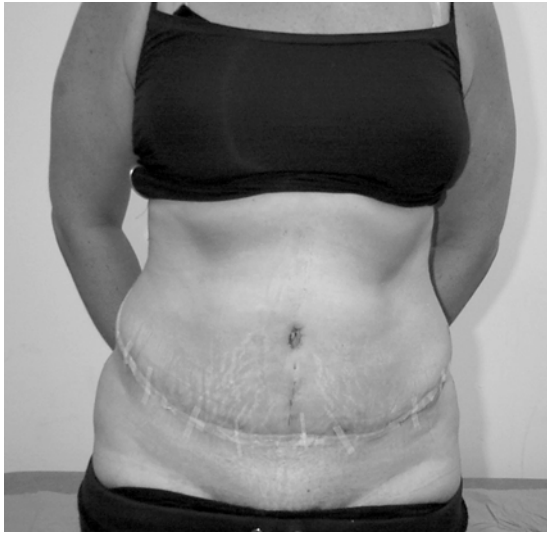


Fig. (3-C): Post-operative, front-view.

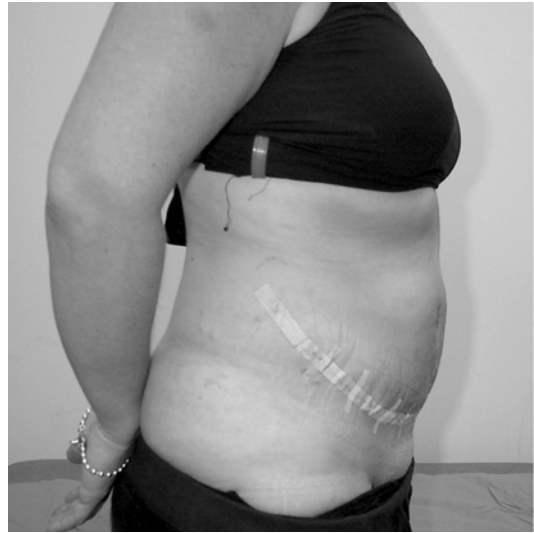

Fig. (3-D): Post-operative, side-view.

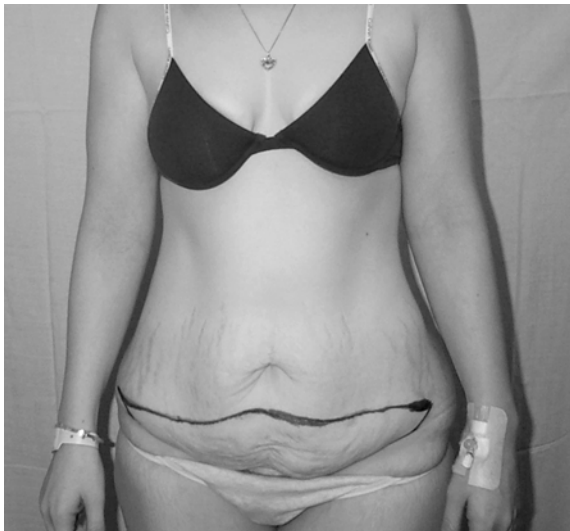


Fig. (4-A): Pre-operative, front-view.

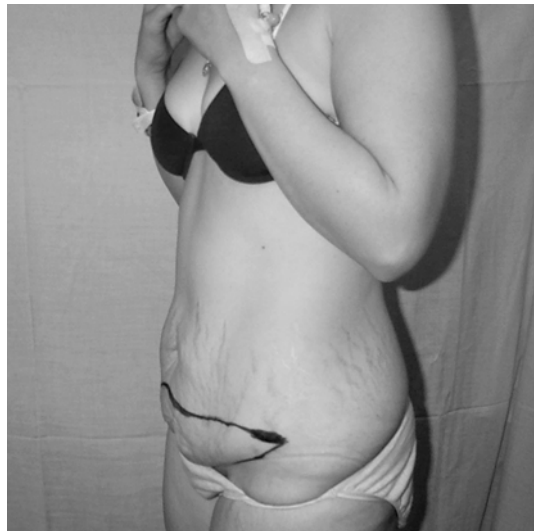

Fig. (4-B): Pre-operative, side-view.

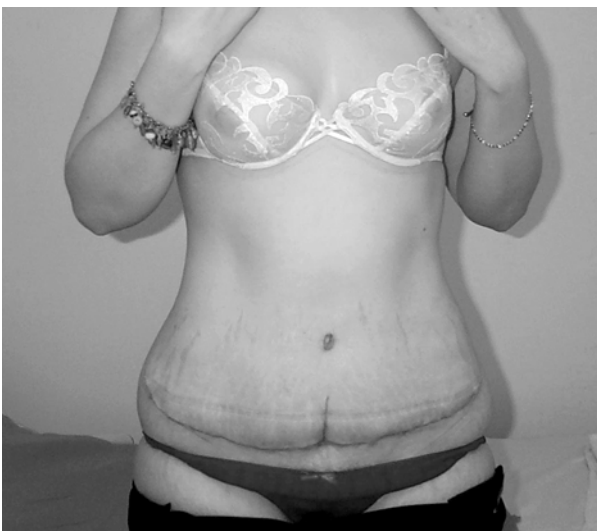

Fig. (4-C): Post-operative, front-view.

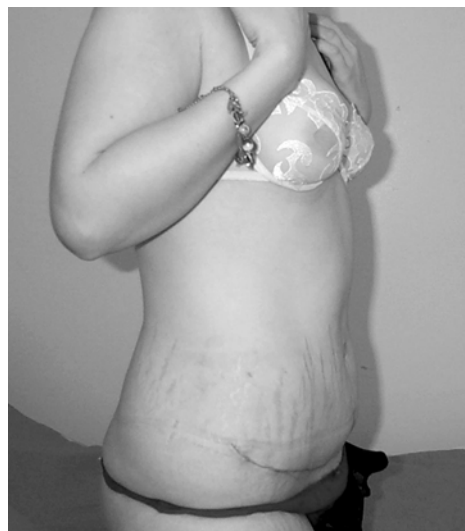

Fig. (4-D): Post-operative, side-view.

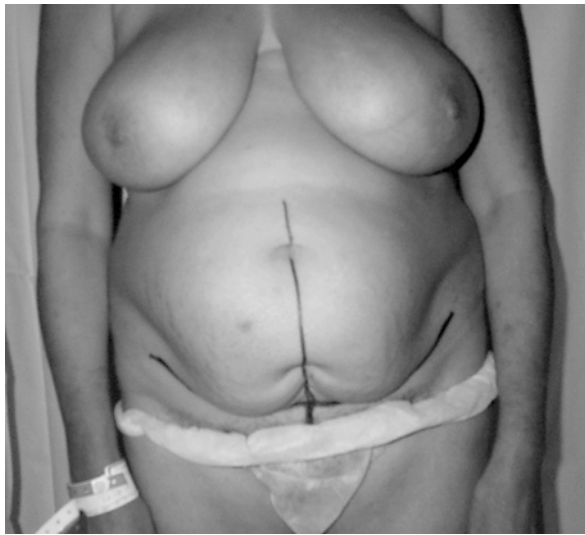

Fig. (5-A): Pre-operative, front-view.

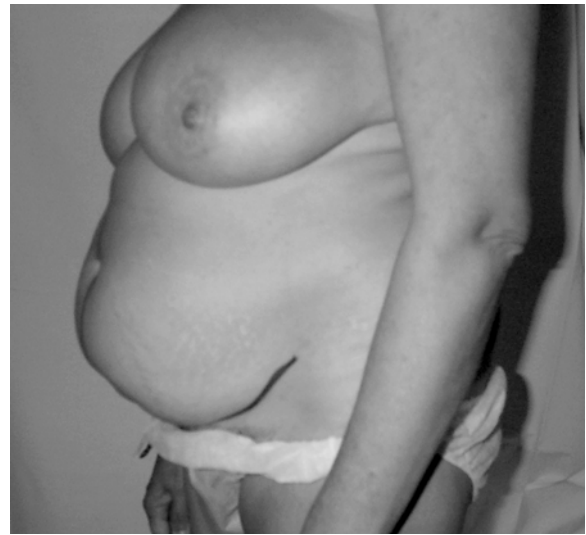

Fig. (5-B): Pre-operative, side-view.

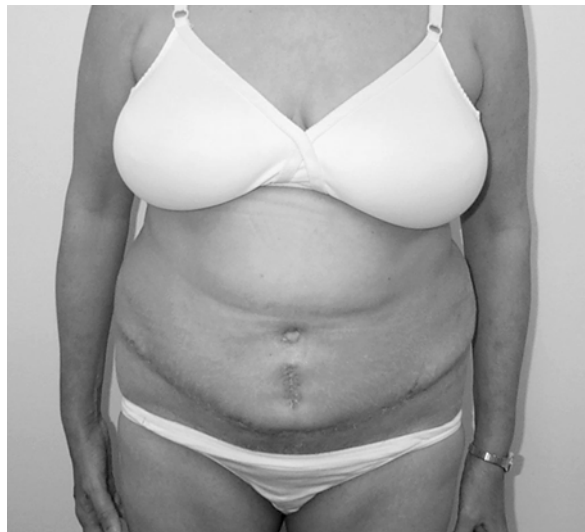

Fig. (5-C): Post-operative, front-view.

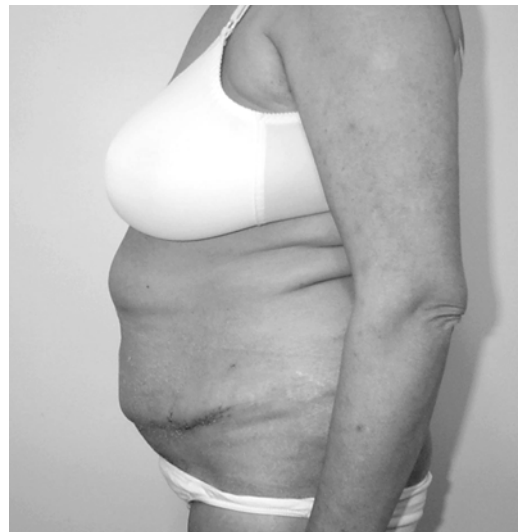

Fig. (5-D): Post-operative, side-view.

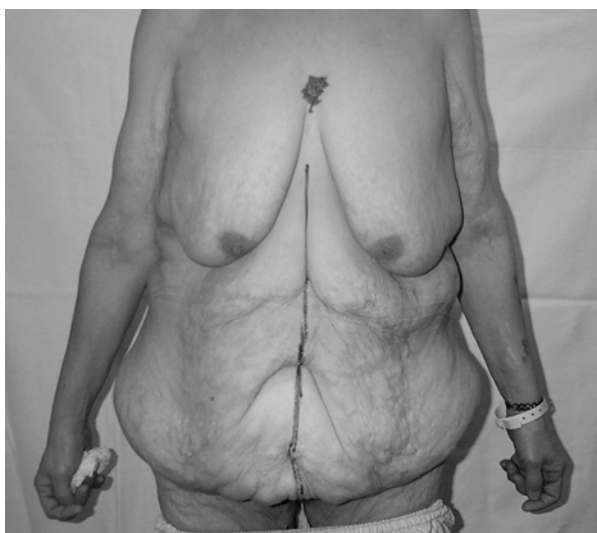

Fig. (6-A): Pre-operative, front-view.

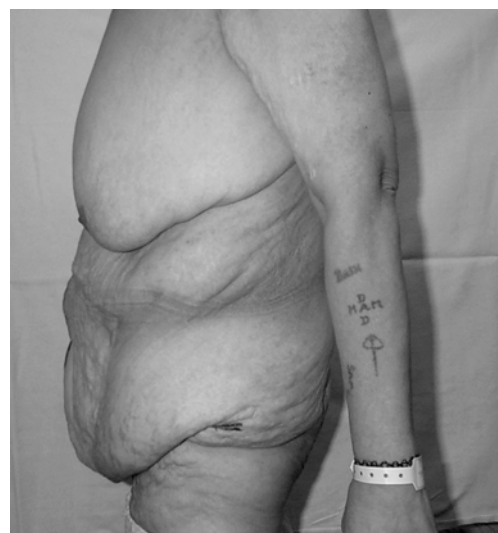

Fig. (6-B): Pre-operative, side-view.

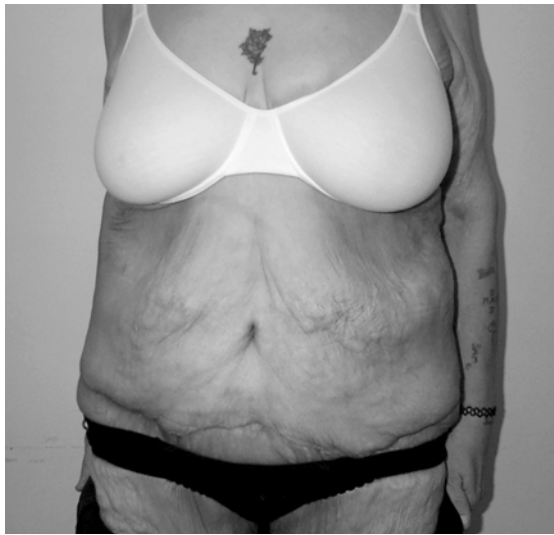

Fig. (6-C): Post-operative, front-view.

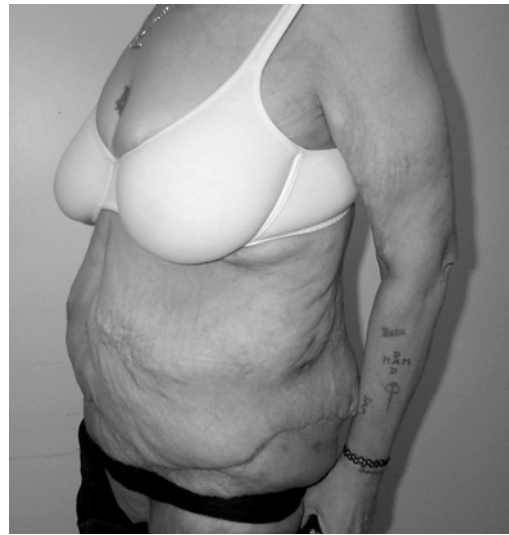

Fig. (6-D): Post-operative, side-view.

## DISCUSSION

Patients seeking abdominal contour improvement are classified into six treatment categories based on anatomical findings and surgical options [7]:

### *Category 1:*

Excess subcutaneous fat, taut skin, taut muscle: Liposuction alone.

### *Category 2:*

Lax skin confined to the infra-umbilical segment, taut muscle, with or without excess fat: Resection of lower abdominal skin and subcutaneous tissue.

### *Category 3:*

Lax skin and lax muscle confined to the infra-umbilical segment with or without excess fat: Infra-umbilical abdominoplasty with muscle tightening.

### *Category 4:*

Mostly lax muscle, minimal or no skin excess with or without excess fat: Complete abdominoplasty without umbilical translocation.

### *Category 5:*

Lax skin of anterior upper and lower abdomen, lax muscle, with or without excess fat: Complete abdominoplasty with umbilical translocation.

### *Category 6:*

Severe circumferential skin laxity, usually secondary to massive weight loss, with or without residual excess fat: Complete circumferential abdominoplasty with umbilical translocation.

Although the classifications are a useful tool, each patient has a unique combination of problems requiring individualization in assessment and selection of an operative plan [7].

The most frequently performed and most effective form of abdominoplasty is complete anterior abdominoplasty with translocation of the umbilicus [8-9].

When the plication of the rectus sheath is required, a non-absorbable suture is used for the first layer of closure, followed by a running layer of absorbable suture. This technique allows the non-absorbable suture to be buried and the superficial sutures to be absorbed, thereby, preventing the formation of palpable knots through the subcutaneous tissue in thinner patients [1].

Post-operative discomfort with activities and the lower quality of contouring results were noticed by the author in patients with weak anterior abdominal muscles who needed plication of the muscular layer. This was alleviated by pre-operative exercises for the abdominal muscles for few months, as shown in the patients studied in this series.

### *Conclusion:*

Exercises for the anterior abdominal muscles for few months before the operation of abdominoplasty, are a useful aid to achieve better quality of contouring and alleviate the post-operative discomfort experienced in the patients, after muscle layer plication, during their activities.

## REFERENCES

- 1- Grazer F.M.: Abdominoplasty. Plastic Surgery, McCarthy J.G., et al., W.B. Saunders company, p 3929-3963, 1990.
- 2- Voloir P.: Operations plastiques sus-aponeurotiques sur la paroi abdominale anterieure. These, Paris, 1960.
- 3- Regnanult P.: Abdominoplasty by the W technique. Plast. Reconstr. Surg., 55: 265, 1975.
- 4- Illouz Y.G.: Body contouring by lipolysis: a 5-year experience with over 3000 cases. Plast. Reconstr. Surg., 72: 591, 1983.
- 5- Kesselring U.K.: Suction curettage to remove excess fat for body contouring (letter to the editor). Plast. Reconstr. Surg., 69: 572, 1982.
- 6- Psillakis J.M.: Plastic surgery to of the abdomen with improvement in the body contour: physio-pathology and treatment of the aponeurotic musculature. Clin. Plast. Surg., 11: 465, 1984.
- 7- Pitman G.H.: Liposuction and body contouring. Grabb and Smith's Plastic Surgery, Fifth edition, edited by S.J. Aston et al., Lippincott-Raven Publishers, Philadelphia, p 669-690, 1997.
- 8- Baroud R. and Moraes M.A.: "Bicycle-handle bar" type of incision for primary and secondary abdominoplasty. Aesth. Plast. Surg., 19: 30, 1995.
- 9- Lockwood T.E.: High-lateral-tension abdominoplasty with superficial fascial system suspension. Plast. Reconstr. Surg., 96: 603, 1995.